

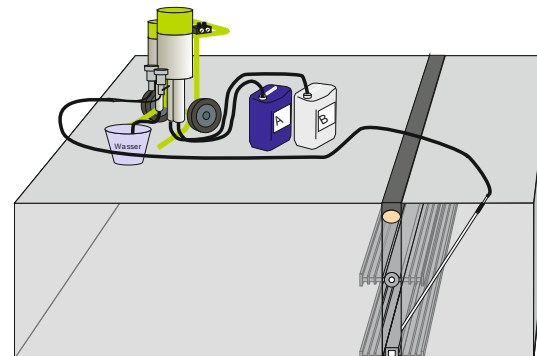
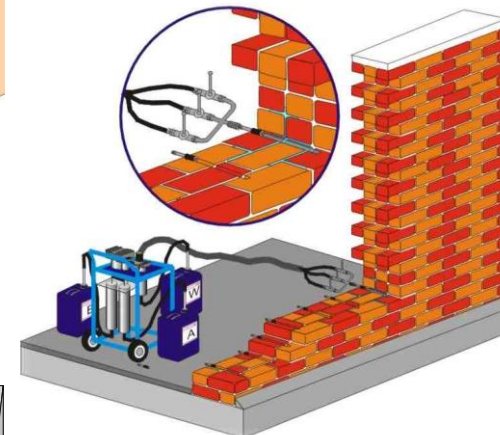
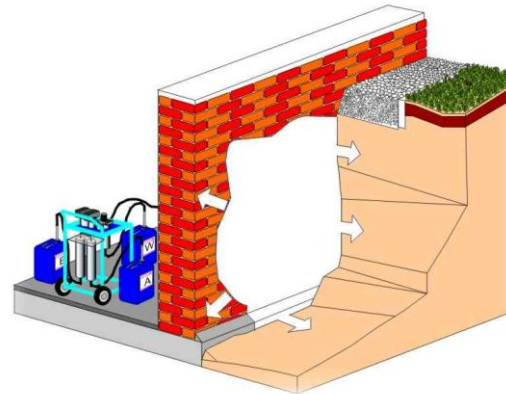
**Injekcioni Gel 3 deo**  
**Ugradnja**

**Septembar, 2015**

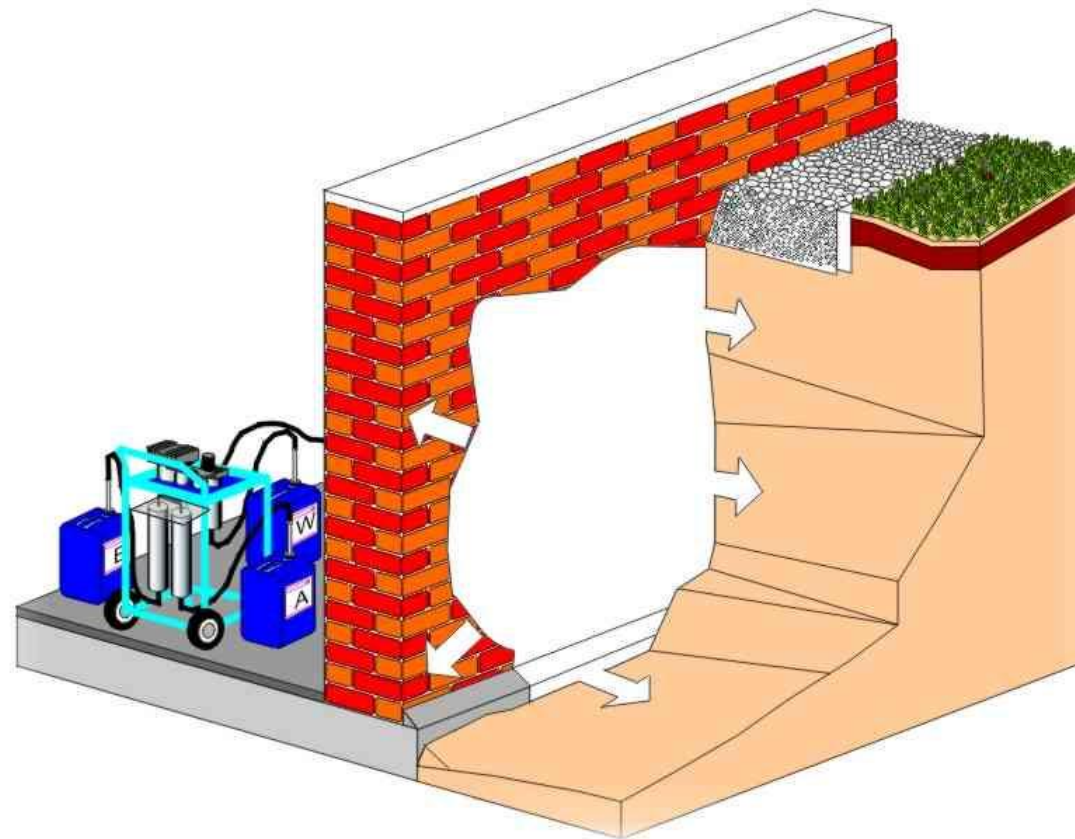
---

## Ugradnja

- Injekciona zavesa
- Injektiranje u zidove
- Injektiranje šupljina




## Injekciona zavesa



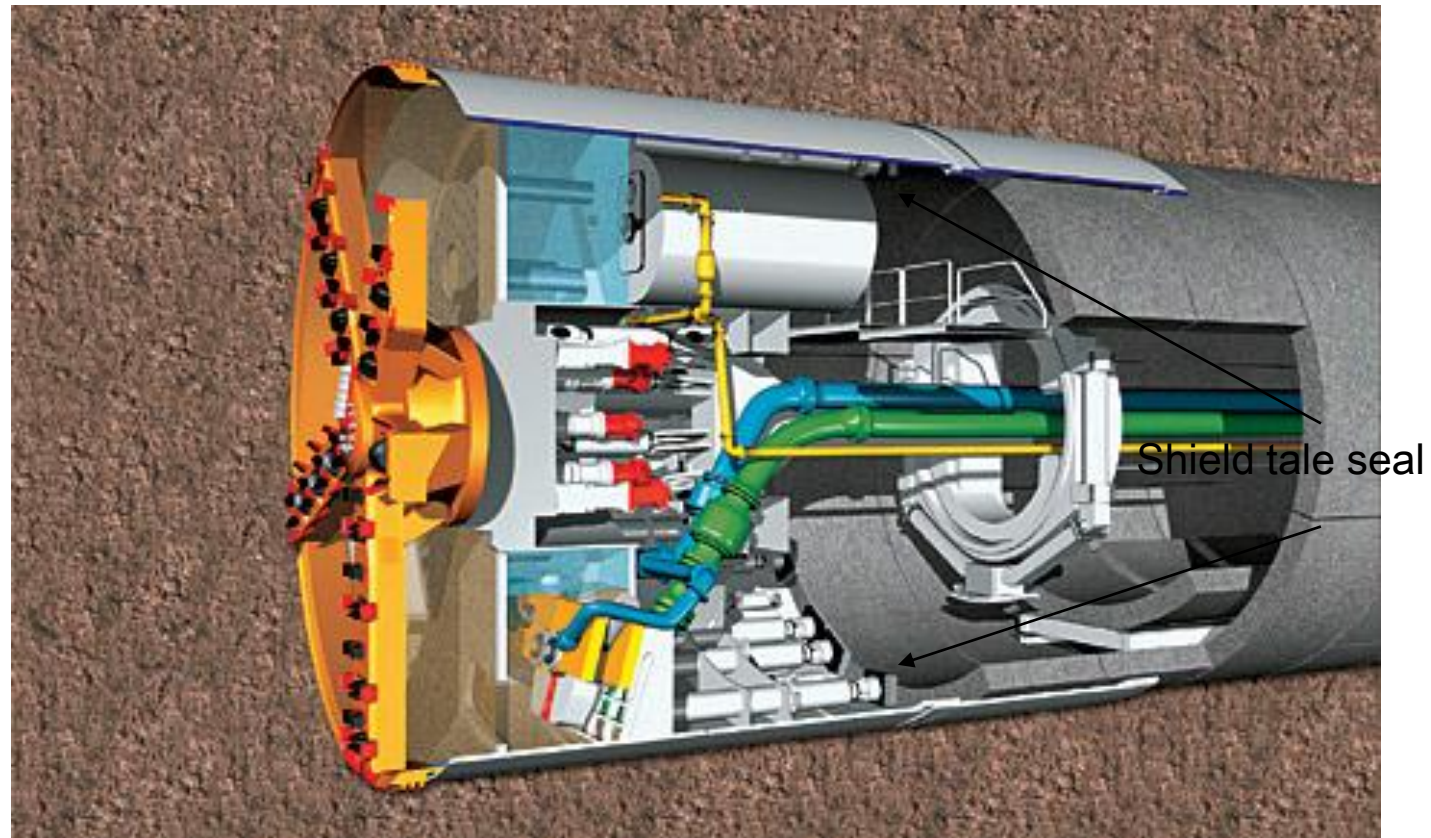
## Test ugradnje



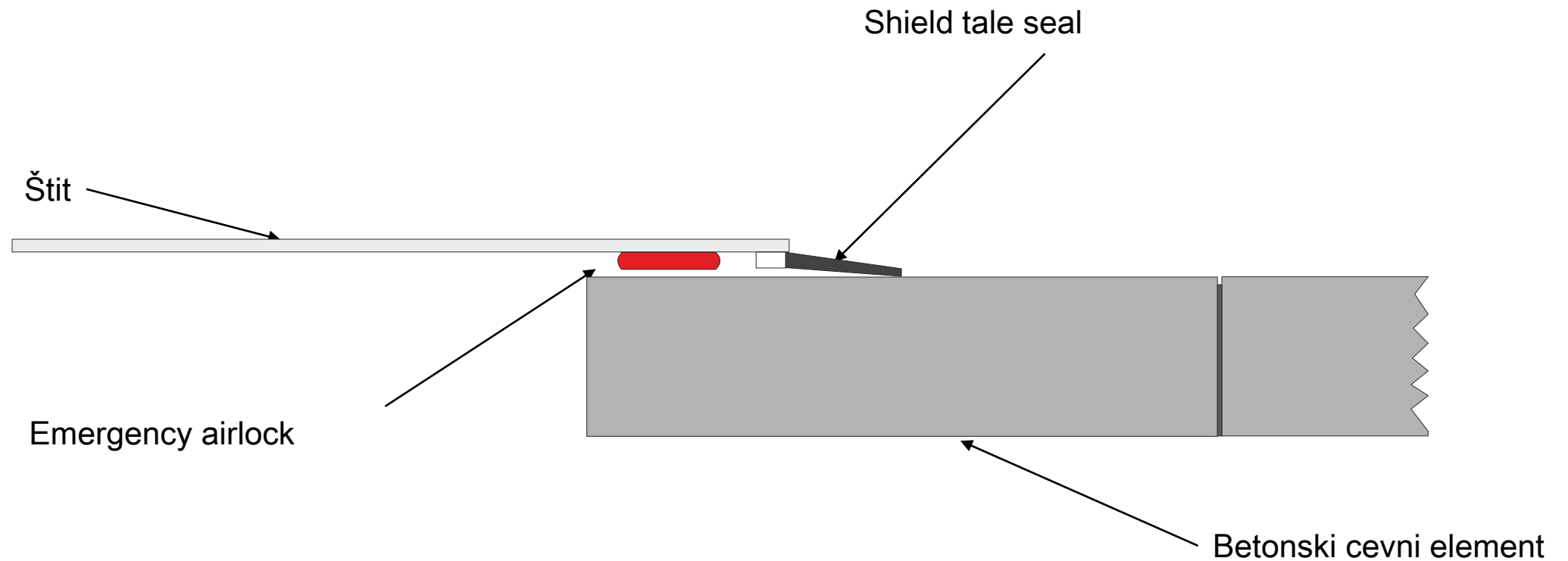
## Injekciona zavesa



**Poseban slučaj: Injekciona zavesa**

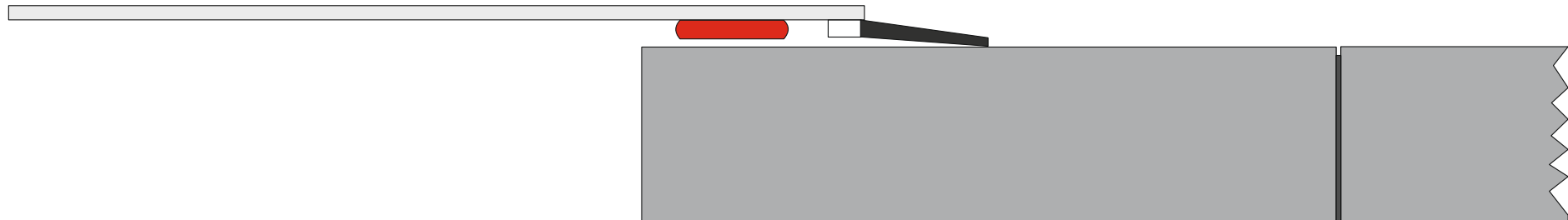


**Sečenje kroz štit i prvi prsten segmenta**

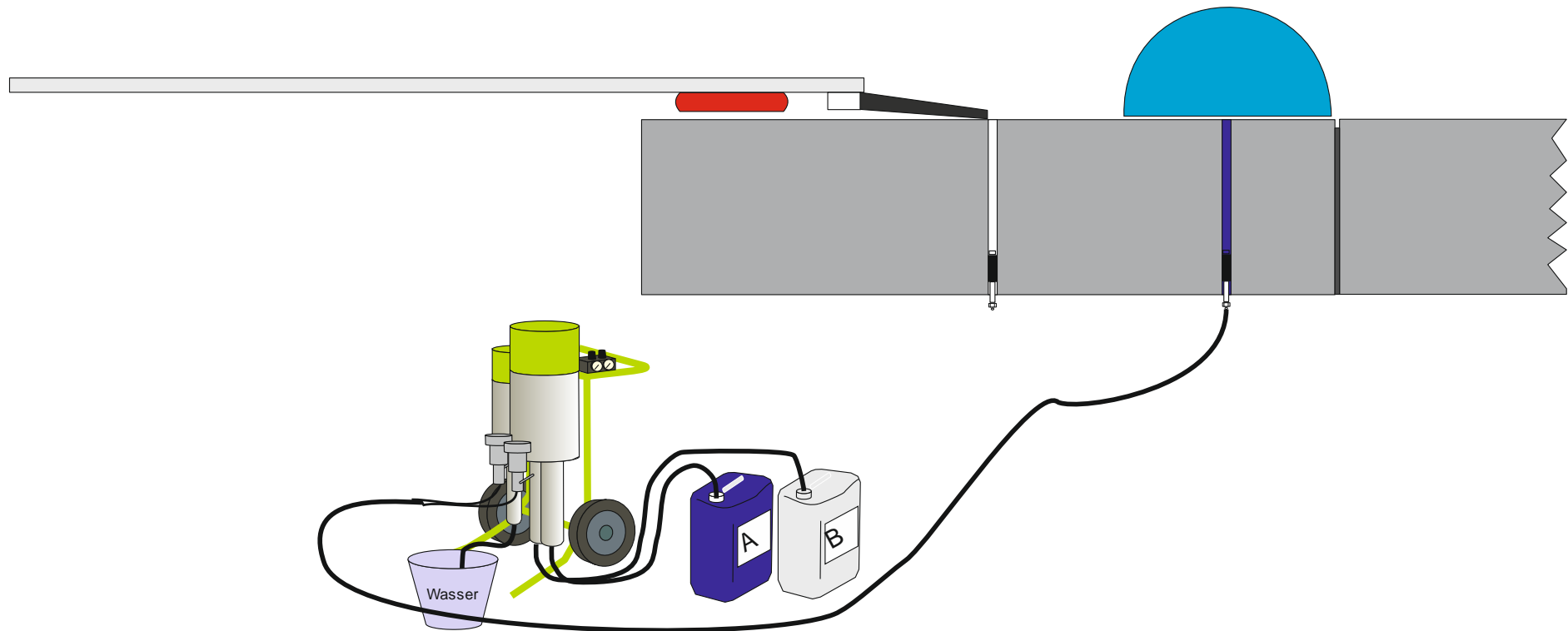


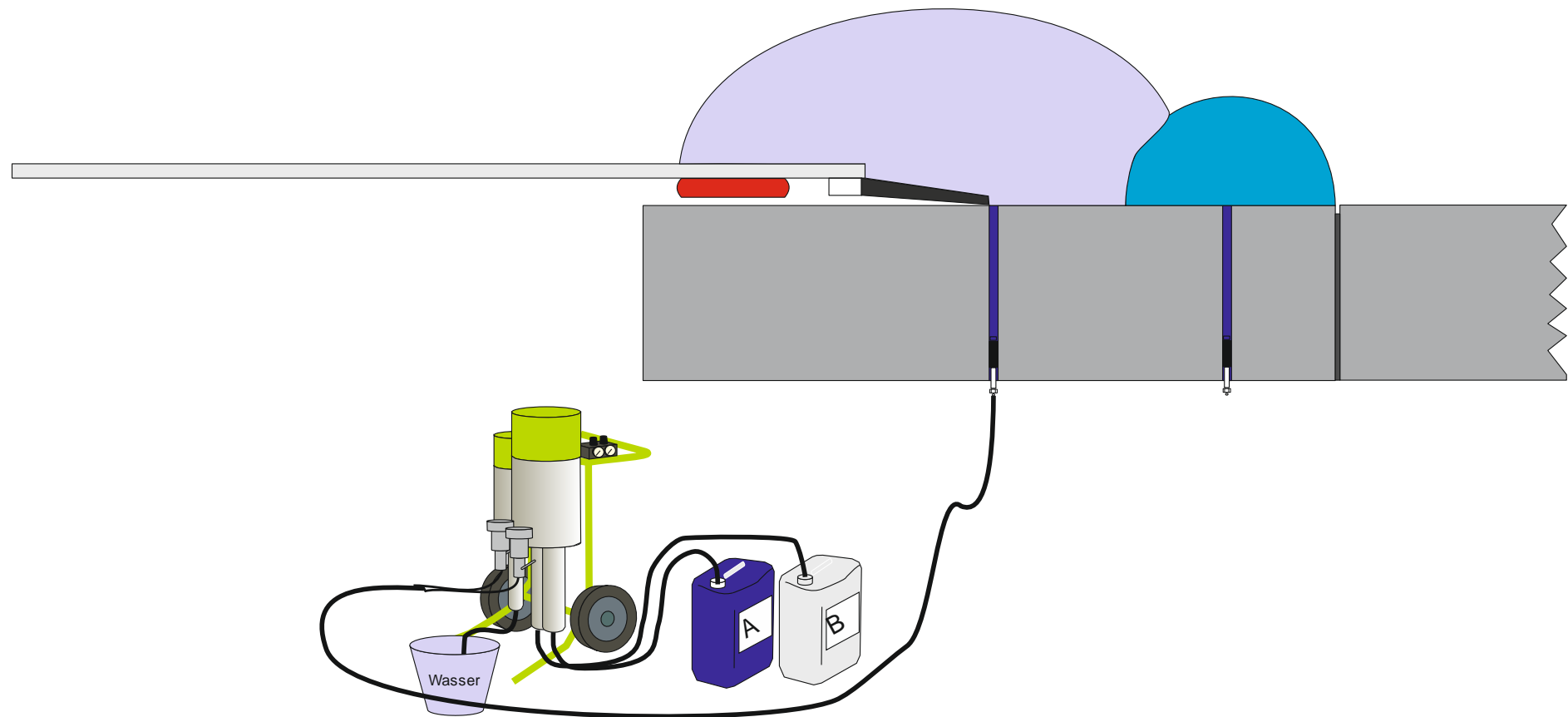
---

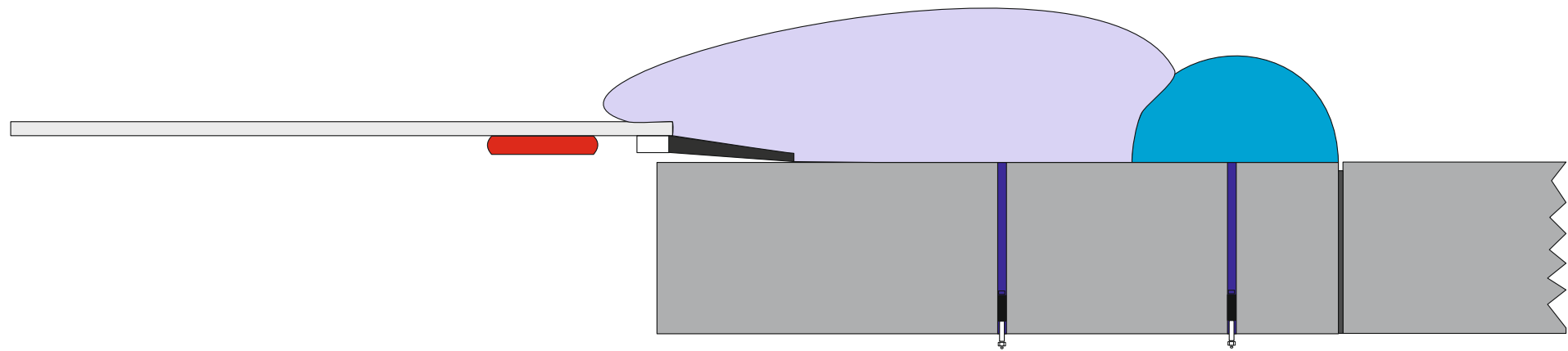
**Rešenje**

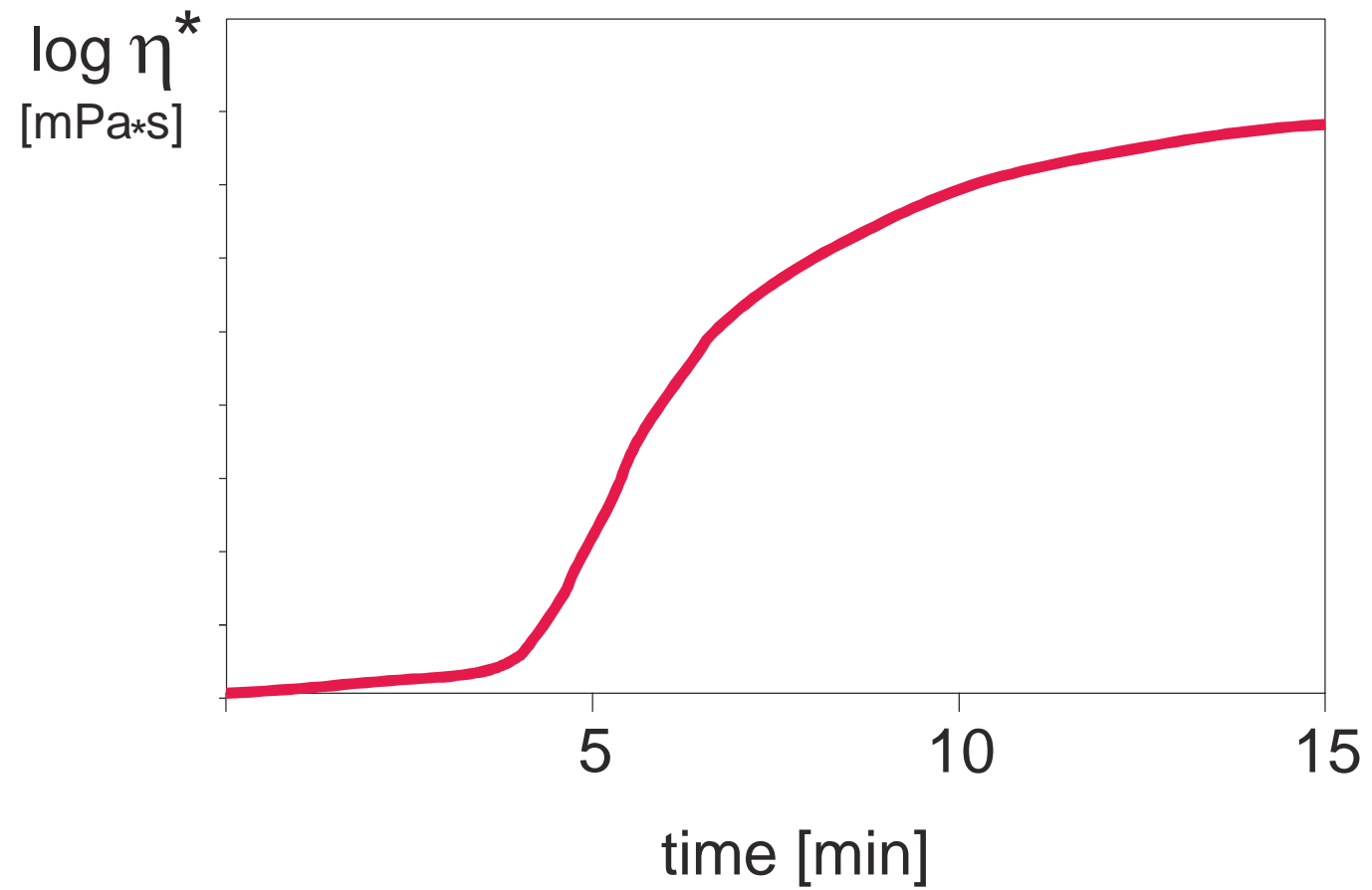




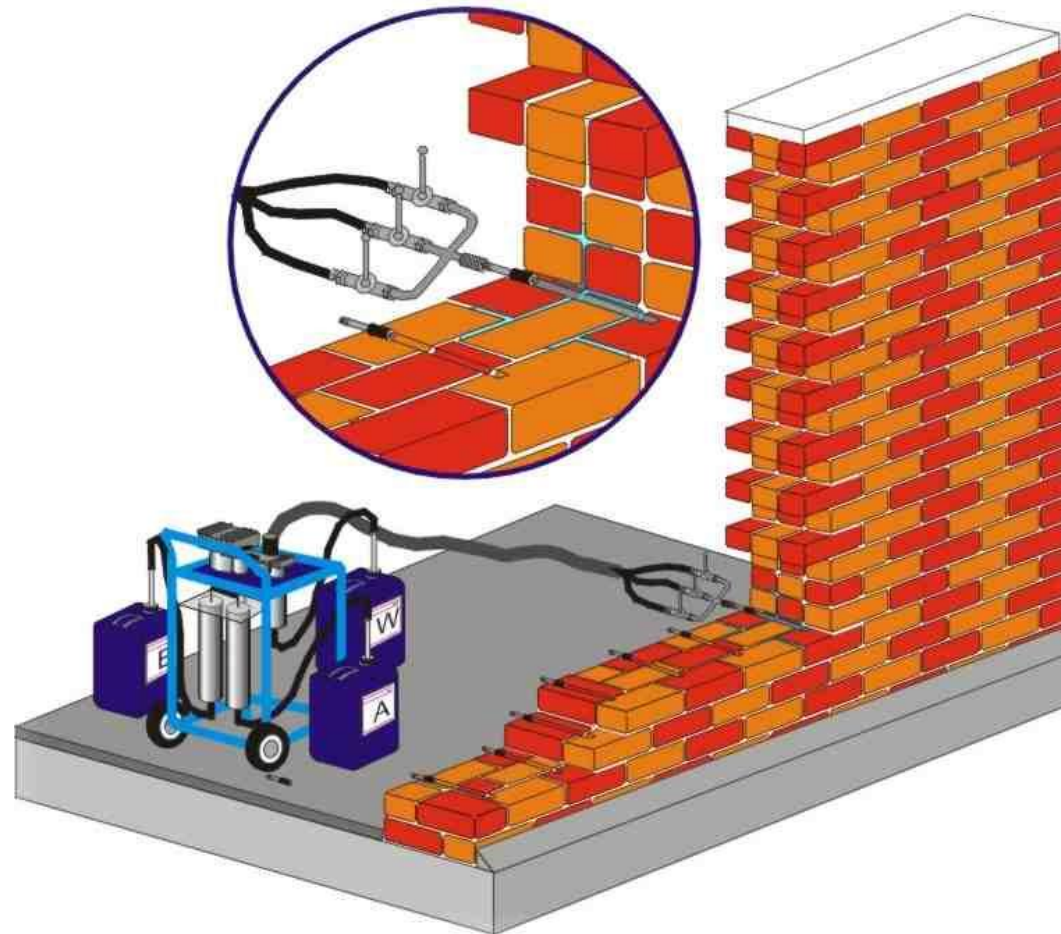









## Injektiranje u zid




## Injektiranje



**izolacija**

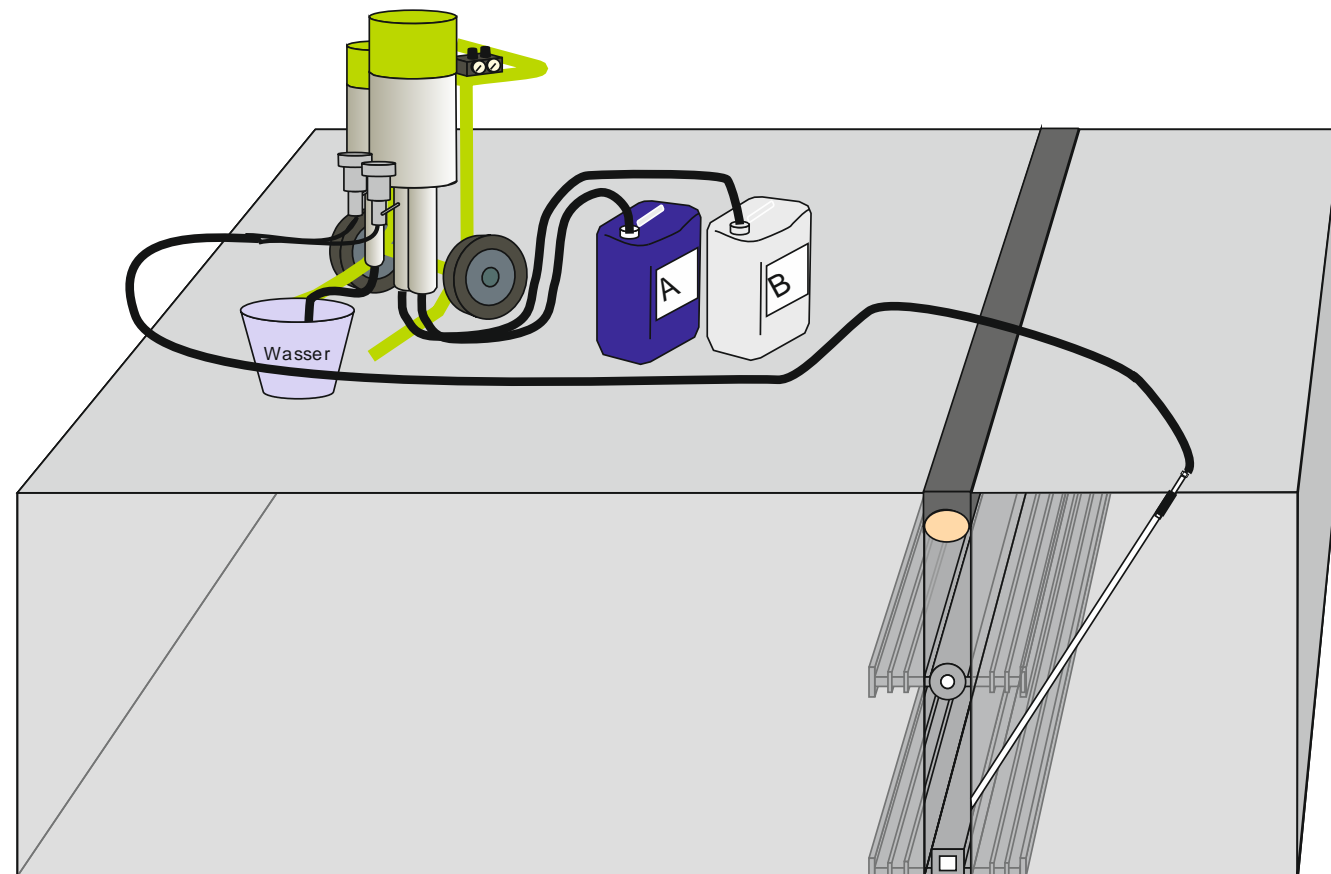


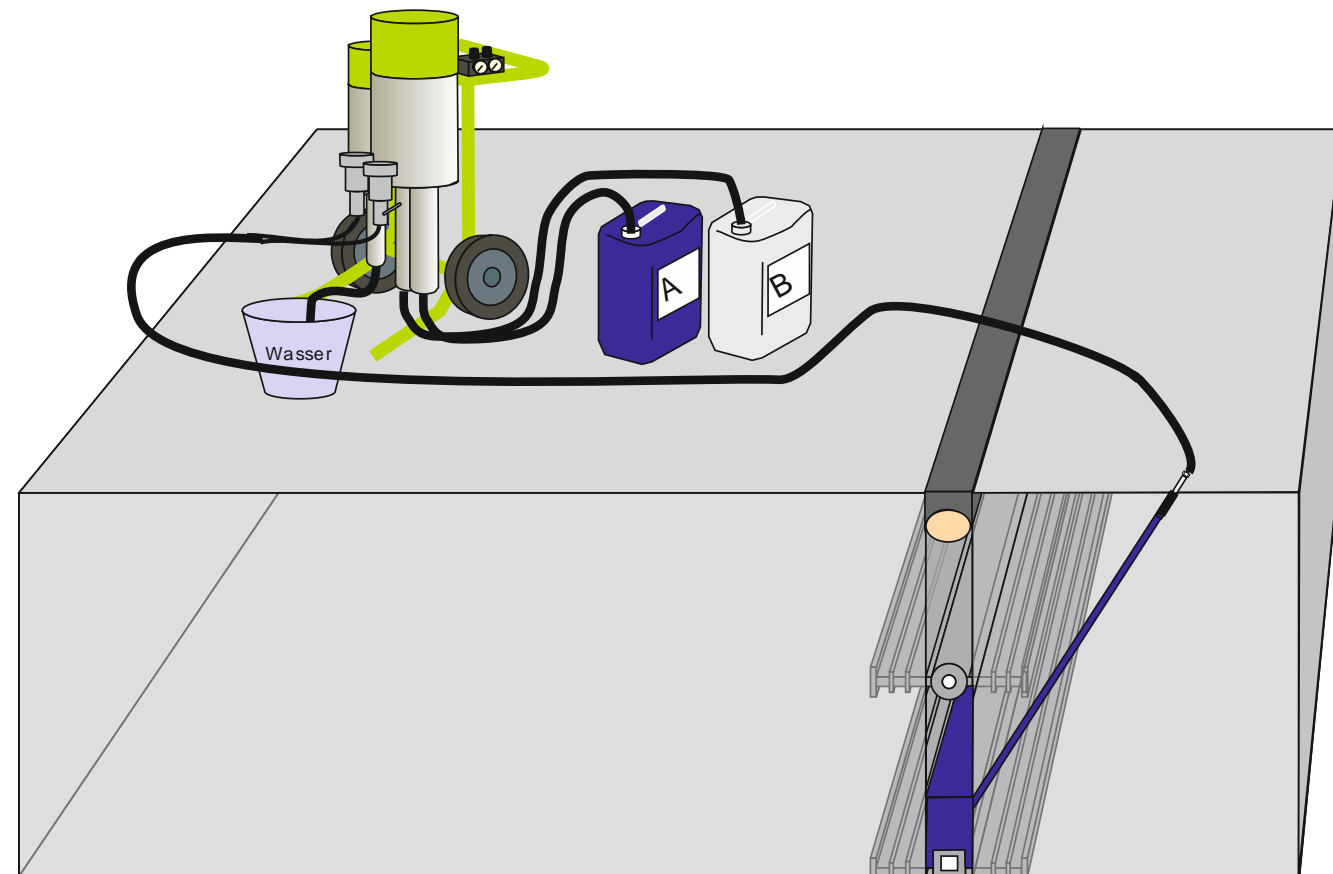
## Injektiranje tunela

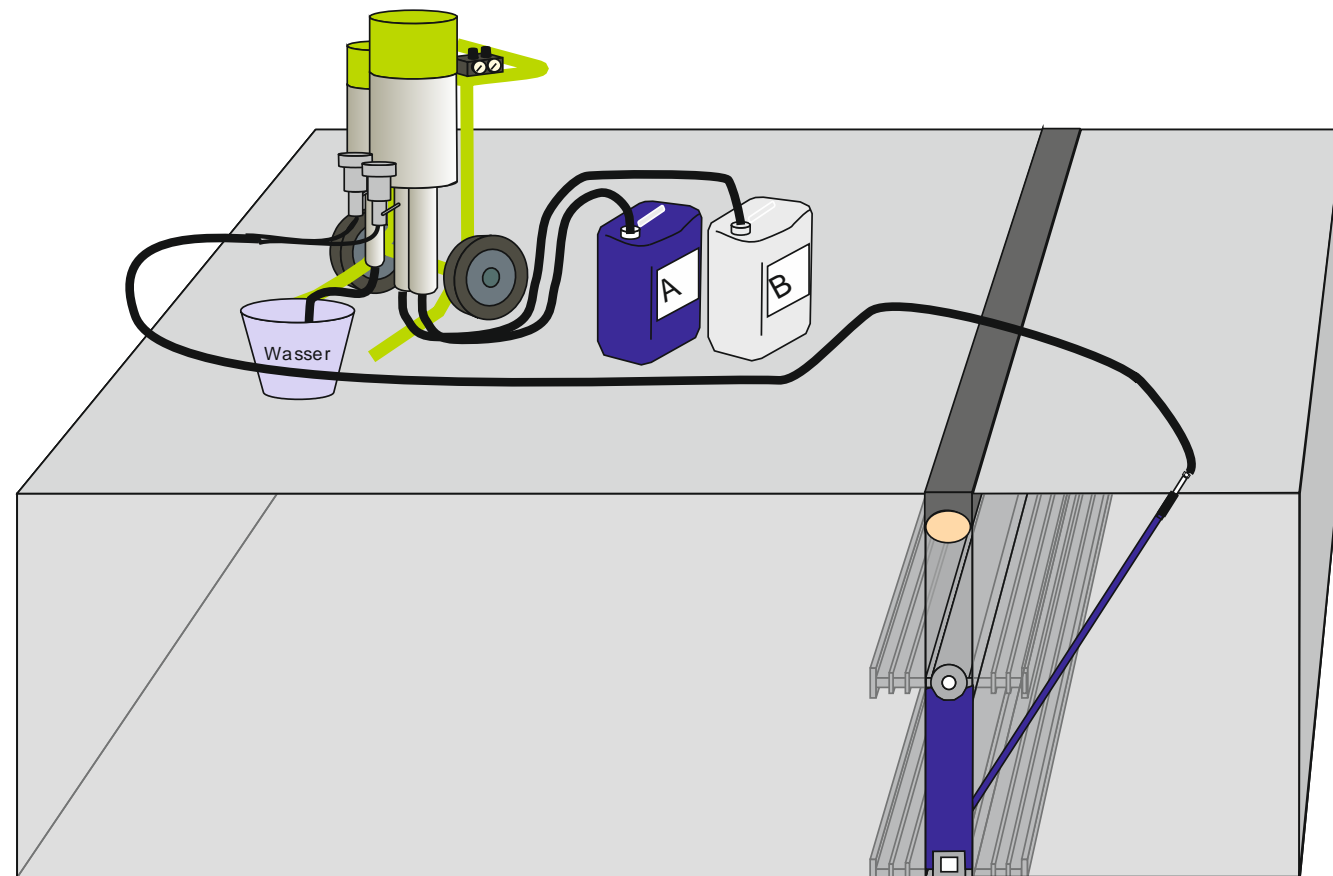




## Injektiranje šupljina







## Injektiranje šupljina

C Injection Void


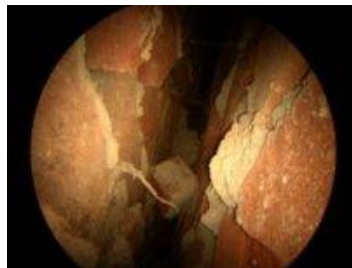
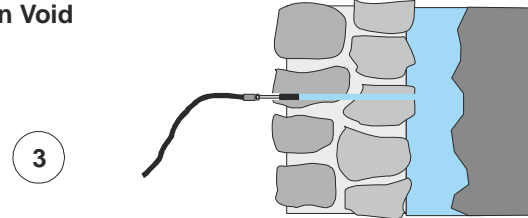


Abbildung 17: Hinterfüllung und wasserführende Adern

